

Name:	Aya Muataz		
Gender:	Female		
DOB:	22 years	File No:	
Referring Doctor:	Dr Sana	Date:	27/3/2025

Pelvic Ultrasound


Report

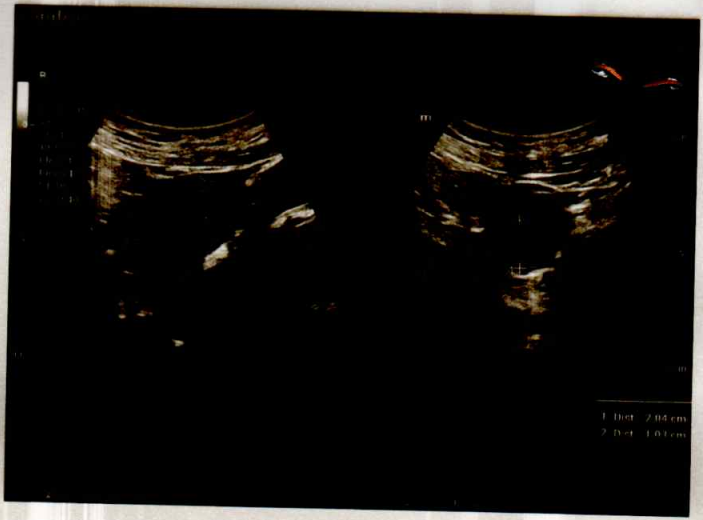- Normal size A/v uterus, homogenous myometrium, empty cavity, endometrial thickness= 9 mm, no SOL .
- Normal RT.ovary volumes and echogenicity.
- Normal LT onary volume and echogenecity , DF seen measuring (20)mm
- no pelvic free fluid is seen.

Conclusion

Regards,

Radiologist: Dr Hana F. Saber





Normal size uterus, homogeneous myometrium, empty cavity.
 Endometrial thickness = 9 mm, no SOL.
 Normal RL ovary volume and echogenicity.
 Normal LT ovary volume and echogenicity. De seen measuring (28mm).
 No pelvic free fluid is seen.

Conclusion

Regards,

Radiologist: Dr. Hana F. Sobhy